

# A Vintage Case with a Novel Treatment for Neurosyphilis: A Case Report

Ahmad Alam<sup>1</sup>, Mohd Ashraf Alam<sup>2\*</sup>, H.S Khan<sup>3</sup>, S.Z. Rahman<sup>4</sup>

<sup>1</sup>Senior Resident, Department of Medicine, JN Medical College. AMU. Aligarh. India

<sup>2</sup>Senior Resident Department of Pharmacology, JN Medical College, AMU. Aligarh. India

<sup>3</sup>Professor Department of Medicine, JN Medical College. AMU. Aligarh. India

<sup>4</sup>Professor Department of Pharmacology, JN Medical College, AMU. Aligarh. India

## ABSTRACT

*Syphilis is a multisystem chronic infection caused by Treponema pallidum. The infection has a multitude of clinical presentation and is often referred to as the 'great imitator'. Neurosyphilis (NS) can have different presentation such as meningitis along with meningovascular complications. With the advent of antibiotic penicillin procaine, however, the number of new syphilitic patients have been decreased, but still few new cases are being reported occasionally. Since the penicillin is now rarely available in the local drug market, the reported rare case of Neurosyphilis at tertiary care hospital of North India was treated by another antibiotic Ceftriaxone successfully after confirmation by syphilis serology and attenuation of signs and symptoms.*

**Keywords:** Syphilis, neurosyphilis, optic atrophy, ceftriaxone in neurosyphilis

DOI: 10.21276/jpds.2019.16.01.05

Received: 25.01.18

Accepted: 23.02.18

## Corresponding Author

Dr. Mohd Ashraf Alam  
 Email: dr.mashrafalam@gmail.com

Copyright: © the author(s) and publisher. JPDS is an official publication of Society of Pharmacovigilance, India.



This is an open access article distributed in accordance with the Creative Commons Attribution Non Commercial (CC BY-NC 4.0) license, which permits others to distribute, remix, adapt, build upon this work non-commercially, and license their derivative works on different terms, provided the original work is properly cited and the use is non-commercial

## INTRODUCTION

Syphilis is a multisystem chronic infection caused by *Treponema pallidum*.<sup>[1,2]</sup> Although there has been a drastic decrease in the number of cases of syphilis with the introduction of penicillin, it is still an important cause of the sexually transmitted diseases in developing countries especially in immunocompromised patients having other STDs like AIDS in the world.<sup>[3,4]</sup>


Syphilis is being classified into four stages namely primary, secondary, latent and tertiary stages based on clinical signs and symptoms. Primary syphilis is characterized by a typical painless syphilitic ulcer called chancre seen at the inguinal region after an incubation period lasting for 2-3 weeks. Secondary syphilis appears weeks or months later in nearly 25% of untreated patients with lymphadenopathy, gastrointestinal abnormalities and central nervous system alterations. However, at the end of the latent period, tertiary syphilis develops in 25% of the untreated patients, which is seen 1-30 years after primary infection.

Tertiary syphilis is of three types viz cardiovascular syphilis, neurosyphilis, and gummatous syphilis. Neurosyphilis is further classified as early and late syphilis. Cerebrospinal fluid (CSF),

meninges and vascular structures are involved in the early stages of neurosyphilis, while in the late stage, cerebral tissue and spinal cord parenchyma are affected.<sup>[5,6]</sup>

## Diagnostic Criteria for Neurosyphilis

- Category 1 - Neuropsychiatric (most common manifestations) disorders (psychosis, delirium, and dementia)
- Category 2 - Cerebrovascular accident (acute, focal neurological deficit compatible with a cerebrovascular accident or radiological evidence of stroke)
- Category 3 - Ocular (presentation with uveitis, visual loss, or optic nerve dysfunction)
- Category 4 - Myelopathy (acute, sub-acute, or chronic dysfunction of the spinal cord, including tabes dorsalis)
- Category 5 - Seizure (presentation with partial seizures, with or without secondary generalization, or myoclonus)

Access this article online	
Website: <a href="http://www.journalofsopi.com">www.journalofsopi.com</a>	Quick Response code 
DOI: 10.21276/jpds.2019.16.01.05	

**How to cite this article:** Alam A, Alam MA, Khan HS, Rahman SZ. A Vintage Case with a Novel Treatment for Neurosyphilis: A Case Report. J Pharmacovig Drug Safety. 2019;16(1):10-12.

**Source of Support:** Nil, **Conflict of Interest:** None

- Category 6 - Brain stem/cranial nerves (signs restricted to the brain stem and cranial nerves) <sup>(7)</sup>

Therefore, neurosyphilis can be manifested with many different symptoms as described above.

## CASE REPORT

A 54-year-old female patient was admitted to the JN Medical Hospital with complaints of transient loss of vision (painless) for two and half months and flashes of light for two months bilaterally. There was no history of pain and diplopia in both eyes. On examination, no weakness of any part of the body and no loss of neurological signs were present. On interrogation, no medical and family history was present.

Eye examination revealed normal visual field with visual acuity of 6/9 and 6/18 and intra ocular pressure of 15 and 14 in right and left eye respectively. Pupils were normal with no Relative Afferent Pupillary Defect (RAPD). On Slit lamp examination, anterior segment was normal in both the eyes. However, on dilated fundus examination (DFE), there was disk edema B/L and optic nerve swelling with peripapillary and vitreous hemorrhage (isolated presumed optic nerve gumma). No other features such as chorioretinitis was seen on DFE.

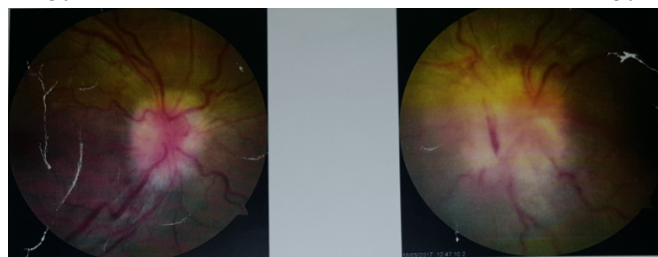
The patient underwent a systemic workup plan, including a complete blood count, tuberculin skin test, chest X-ray, syphilis serology and ACE enzyme test. All investigations were found negative except syphilis serology. The value of Treponema pallidum hemagglutination assay (TPHA) was 1/2560 dilution. Venereal Diseases Research Laboratories (VDRL) and Rapid Plasma Reagin (RPR) tests were also found positive. HIV status was non-reactive. CSF analysis was normal; CSF VDRL was non-reactive. With this history along with the clinical findings, together with the results of serology, a presumptive diagnosis of neurosyphilis category 3 (Ocular presentation with uveitis, visual loss, or optic nerve dysfunction) was made and started treatment with Ceftriaxone 4g/d IV and Dexamethasone 12g/d IV for 14 days.

The patient showed recovery of eye defect as compared before and after the treatment (picture 1-4). There was marked improvement in fundus disc appearance especially in left eye (Picture.). Visual acuity restored to 6/9 in both eyes.

Before Treatment

OD 30

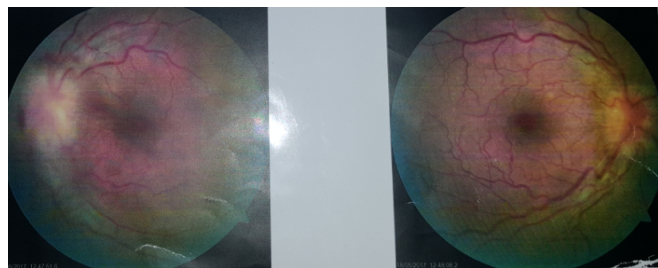
OS 30



Slide 1

OS 45

OD 45

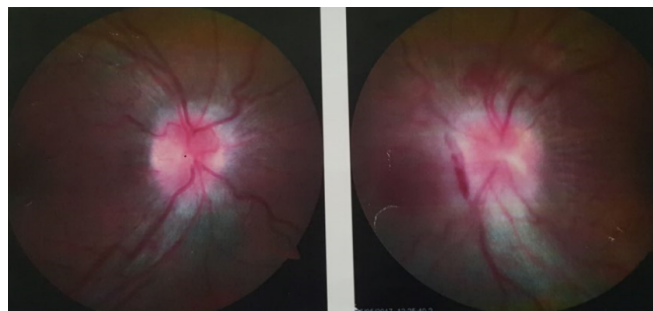


Slide 2

After Treatment

OD 30

OS 30



Slide 1

## DISCUSSION

Ocular involvement in Syphilis is rare and typically occurs in primary and secondary syphilis. There are no pathognomonic signs and the ability of syphilis to mimic other disease often lead to misdiagnosis and delay in treatment. The differential diagnosis includes infectious disease such as tuberculosis and non-infectious disease such as sarcoidosis. The most common ocular manifestation of syphilis is uveitis.<sup>[8,9]</sup> However posterior segment involvement, including chorioretinitis, retinitis, vasculitis, vitritis and panuveitis, can also occur.<sup>[10-12]</sup>

Chronic Gummatous or granulomatous inflammation of the ocular structure is typical of late stage of disease.

CDC recommends lumbar puncture in all patients with ocular syphilis, to detect neurosyphilis even in absence of clinical neurological findings.

The diagnosis of neurosyphilis is based upon CSF fluid pleocytosis and presence of positive VDRL. CSF VDRL testing is highly specific and positive result confirms neurosyphilis.

The VDRL test has low sensitivity to detect syphilis and therefore a negative VDRL doesn't rule out Neurosyphilis. Specific treponemal test are not very useful to detect neurosyphilis because antitreponemal IgG antibodies pass the intact blood brain barrier and a positive result is no proof of Neurosyphilis. MRI was negative for cerebrovascular disease, space occupying mass lesion and vascular dementia.

Ocular syphilis is treated exactly the same way as neurosyphilis. Since benzathine penicillin doesn't cross blood brain barrier aqueous penicillin G or procaine penicillin G plus probenecid should be given for 10-14 days. For patients with ocular syphilis in tertiary stage a 3-week course of benzathine penicillin should be added. CDC, sexually transmitted disease guidelines 2015 suggest that Ceftriaxone may be used as an alternative in penicillin allergic patients with neurosyphilis.<sup>[13,14]</sup>

Inj. Procaine Penicillin was not available in the local market, she was thus prescribed the alternative Ceftriaxone.

Ceftriaxone is known have good CNS penetration. A dose of 1 gm daily can achieve level well above MIC for treponema pallidum of 0.0006 µg/ml. <sup>(15)</sup> It also differs from other cephalosporins by having an unusually long serum half-life of approximately 7 hours.<sup>[16]</sup>

However there have been reports that IM ceftriaxone may not be adequate treatment for Neurosyphilis. A retrospective study of HIV individuals treated with ceftriaxone for asymptomatic neurosyphilis revealed a 23% failure rate.<sup>[17]</sup>

The patient in our case has evidence of symptomatic neurosyphilis in form of ocular involvement, she received 14 days of Ceftriaxone 2g/d IV. There was marked improvement in her visual field acuity as well as fundus appearance.

There are few other reports of successful treatment of symptomatic neurosyphilis in HIV negative individuals with ceftriaxone, but none of them have been reported in India.

## CONCLUSION

This case report suggest that ceftriaxone may be a useful alternative in HIV negative patients with neurosyphilis.

## REFERENCES

1. Bharucha NE. Infections of the nervous system. In: Bradley WG, Daroff RB, Fenichel GM, editors. *Neurology in Clinical Practice*. 3th edition. London: ButterworthHeinemann; 2000. pp. 1334–5.
2. Adams RD, Victor M, Ropper AH. *Principles of Neurology*. 7th edition. New York: Mc GrawHill Companies; 2000. pp. 722–8.
3. Schmidt RP. Neurosyphilis. In: Joynt RJ, editor. *Clinical Neurology*. Revised edition. Vol. 2. Philadelphia: Lippincott Williams & Wilkins; 1992. pp. 1–23.
4. Berger JR. Neurosyphilis in human immunodeficiency virus type 1seropositive individuals. A prospective study. *Arch Neurol*. 1991;48:700–2. [PubMed]
5. Merritt HH, Adams RD, Solomon HC. *Neurosyphilis*. Oxford, New York: 1946.
6. Stokes JH, Beerman H, Ingraham NR. *Modern Clinical Syphilology: Diagnosis, Treatment, Case Study*. 3rd ed. Philadelphia: WB Saunders; 1944.
7. Timmermans M, Carr J. Neurosyphilis in the modern era *Journal of Neurology, Neurosurgery & Psychiatry* 2004; 75:1727-1730.
8. Tamesis RR, Foster CS. Ocular syphilis. *Ophthalmology* 1990;97:1281-7.
9. Barile GR, Flynn TE. Syphilis exposure in patients with uveitis. *Ophthalmology* 1997;104:1605-9
10. Chao J, Khurana RN, Fawzi AA. Syphilis: Reemergence of an old adversary. *Ophthalmology* 2006;113:2074-9.
11. Shalaby IA, Dunn JP, Semba RD, Jabs DA. Syphilitic uveitis in human immunodeficiency virus-infected patients. *Arch Ophthalmol* 1997;115:469-73.
12. Ormerod LD, Puklin JE, Sobel JD. Syphilitic posterior uveitis: Correlative findings and significance. *Clin Infect Dis* 2001;32:1661-73.
13. Hook EW, 3rd, Baker-Zander SA, Moskovitz BL, et al. Ceftriaxone therapy for asymptomatic neurosyphilis: case report and Western blot analysis of serum and cerebrospinal fluid IgG response to therapy. *Sex Transm Dis* 1986; 133(3 Suppl):185–8.
14. Shann S, Wilson J. Treatment of neurosyphilis with ceftriaxone. *Sex Transm Infect* 2003;79:415–6
15. Marra CM, Slatter V, Tartaglione TA, et al. Evaluation of aqueous penicillin G and ceftriaxone for experimental neurosyphilis. (letter) *J Infect Dis* 1992; 165: 396–7.
16. Steele RW. Ceftriaxone therapy of meningitis and serious infections. *Am J Med* 1984; 77(4C):50–3
17. Dowell ME, Ross PG, Musher DM, et al. Response of latent syphilis or neurosyphilis to ceftriaxone therapy in persons infected with human immunodeficiency virus. *Am J Med* 1992-93: 481–8

